

Moore: The Developing Human, 9th Edition

Chapter 01: Gametogenesis and Fertilization

Test Bank

MULTIPLE CHOICE

Directions: Each group of questions below consists of a numbered list of descriptive words or phrases accompanied by a diagram with certain parts indicated by letters or by a list of lettered headings. For each numbered word or phrase, select the lettered part or heading that matches it correctly and then insert the letter in the space to the right of the appropriate number. Sometimes more than one numbered word or phrase may be correctly matched to the same lettered part or heading.

1. _____ Haploid nuclei that fuse to form a zygote
- Polar body
 - Capacitation
 - Acrosome
 - Zona pellucida
 - Pronuclei

ANS: E

The male and female pronuclei are the haploid nuclei of the sperm and oocyte, respectively. They fuse during fertilization to form the diploid nucleus of a zygote. The nucleus occupies most of the head of the sperm, and after it enters the oocyte, it swells to form the male pronucleus. The pronuclei are about equal in size and show similar features.

2. _____ Changes occur in it that inhibit entry of sperm
- Polar body
 - Capacitation
 - Acrosome
 - Zona pellucida
 - Pronuclei

ANS: D

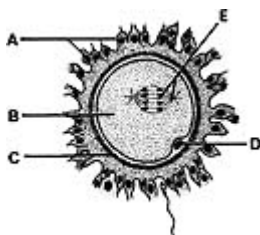
The zona pellucida undergoes changes, called the zona reaction, when a sperm contacts the cell membrane of a secondary oocyte. These changes, caused by the release of substances from the oocyte, prevent other sperms from passing through the zona pellucida and entering the oocyte.

3. _____ Contains enzymes that digest a path for the sperm
- Polar body
 - Capacitation
 - Acrosome
 - Zona pellucida

e. Pronuclei

ANS: C

The acrosome is a caplike structure that invests the anterior half of the head of the sperm. It contains enzymes that pass through perforations in its wall and digest a path for the sperm to follow through the zona pellucida to fertilize the oocyte.



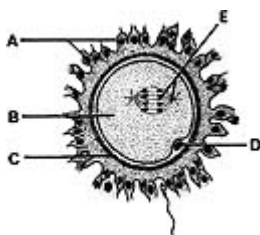
4.

_____ Polar body

- a. A
- b. B
- c. C
- d. D
- e. E

ANS: D

The first polar body forms during the first meiotic division. Note that it is inside the zona pellucida with the secondary oocyte. Although it may divide into two polar bodies, these cells degenerate. The secondary oocyte receives the same number of chromosomes as the polar body; however, it gets almost all the cytoplasm.



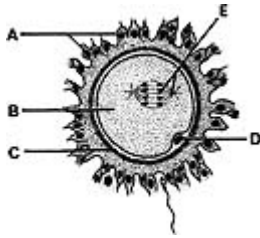
5.

_____ Zona pellucida

- a. A
- b. B
- c. C
- d. D
- e. E

ANS: C

The zona pellucida surrounds the secondary oocyte and the polar body. This membrane is surrounded by a layer of follicular cells called the corona radiata. The zona pellucida appears homogeneous in the fresh condition, but under the electron microscope it appears granular and shows some concentric layering.

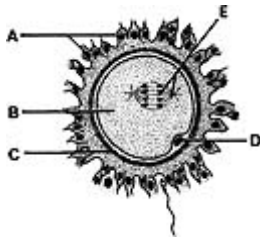


6. _____ Meiotic spindle

- a. A
- b. B
- c. C
- d. D
- e. E

ANS: E

Contact of a sperm with the cell membrane of the oocyte stimulates the secondary oocyte to complete its second meiotic division. This contact also brings about the zona reaction, preventing entry of more sperms. The sperm penetrates the cell membrane of the secondary oocyte and then passes into the cytoplasm of the oocyte, leaving its cell membrane outside the oocyte.

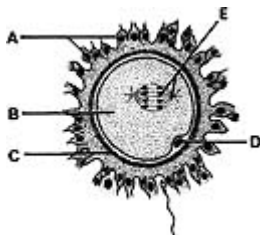


7. _____ Corona radiata

- a. A
- b. B
- c. C
- d. D
- e. E

ANS: A

The corona radiata consists of one or more layers of follicular cells that surround the zona pellucida, the polar body, and the secondary oocyte. The corona radiata is dispersed during fertilization by enzymes released from the acrosomes of the sperms that surround the oocyte.

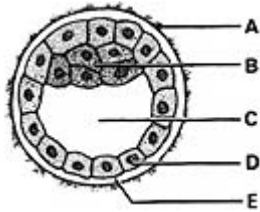


8. _____ Haploid cell

- a. A
- b. B
- c. C
- d. D
- e. E

ANS: D

The polar body is the labeled haploid cell formed during the first meiotic division of the oocyte. The sperm is also a haploid cell zygote.



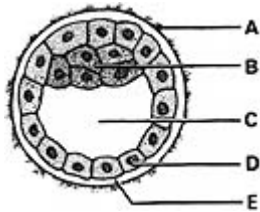
9.

_____ Embryoblast

- a. A
- b. B
- c. C
- d. D
- e. E

ANS: B

The embryoblast (inner cell mass) is recognizable about 4 days after fertilization. It is derived from the central cells of the morula. The embryoblast gives rise to the embryo and some extraembryonic tissues.



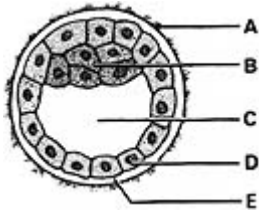
10.

_____ Gives rise to part of the placenta

- a. A
- b. B
- c. C
- d. D
- e. E

ANS: D

The trophoblast gives rise to the embryonic part of the placenta; the other part is derived from the endometrium. When the trophoblast becomes lined by extraembryonic somatic mesoderm, the combined layers are called the chorion. The trophoblast forms no part of the embryo.



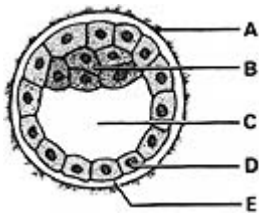
11.

_____ Gives rise to the hypoblast

- a. A
- b. B
- c. C
- d. D
- e. E

ANS: B

At the end of the first week, differentiation of the embryoblast gives rise to the hypoblast. It appears as a flattened layer on the ventral surface of the inner cell mass. Later, it forms the roof of the umbilical vesicle (yolk sac) and is incorporated into the embryo as the lining of the primordial gut.



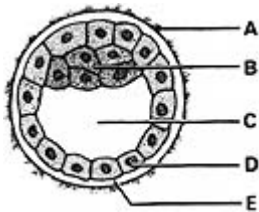
12.

_____ Degenerates and disappears

- a. A
- b. B
- c. C
- d. D
- e. E

ANS: A

The zona pellucida begins to degenerate about 4 days after fertilization as the blastocyst begins to expand rapidly. Implantation of the blastocyst begins on the sixth day.



13.

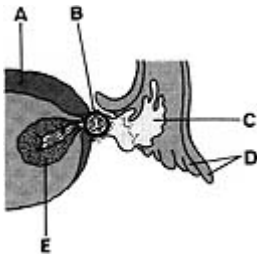
_____ Blastocystic cavity

- a. A
- b. B
- c. C
- d. D

e. E

ANS: C

The blastocystic cavity forms as fluid passes into the morula from the uterus and accumulates. The spaces around the central cells of the morula coalesce to form the blastocystic cavity, converting the morula into a blastocyst. The uterine fluid in the blastocystic cavity bathes the ventral surface of the embryoblast and probably supplies nutrients to the embryonic cells.

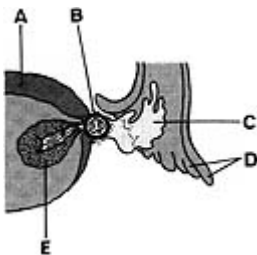


14. _____ Once filled the cavity of the ovarian follicle

a. A
b. B
c. C
d. D
e. E

ANS: C

Follicular fluid fills the cavities of mature ovarian follicles. When the stigma of the follicle ruptures at ovulation, the oocyte is expelled with the fluid from the follicle and the ovary in a few seconds. The expulsion of the oocyte and the fluid is the result of intrafollicular pressure and, possibly, ovarian smooth muscle contraction.

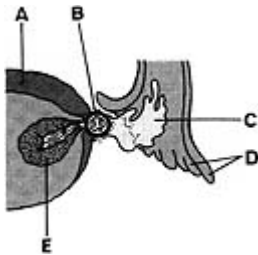


15. _____ Develops under luteinizing hormone influence

a. A
b. B
c. C
d. D
e. E

ANS: E

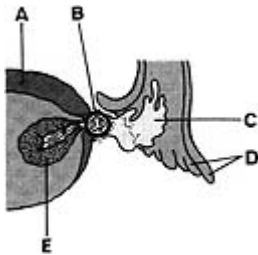
The corpus luteum develops under the influence of the luteinizing hormone. It produces progesterone and some estrogen. These hormones act on the endometrium, bringing about the secretory phase and preparing the endometrium for implantation of a blastocyst. If the oocyte is fertilized, the corpus luteum enlarges into a corpus luteum of pregnancy and increases its hormone production. If the ovum is not fertilized, the corpus luteum begins to degenerate about 9 days after ovulation and is called a corpus luteum of menstruation.



16. _____ Produces progesterone
- A
 - B
 - C
 - D
 - E

ANS: E

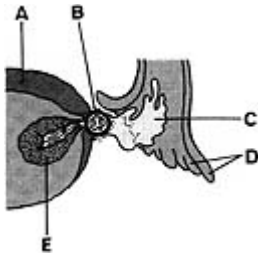
The corpus luteum usually produces progesterone for about 9 days. If the oocyte is fertilized, it produces progesterone until about the end of the fourth month of pregnancy.



17. _____ Expelled with the follicular fluid
- A
 - B
 - C
 - D
 - E

ANS: B

The secondary oocyte is expelled with follicular fluid at ovulation. Ovulation is under FSH and LH influence and occurs through the ruptured stigma. The oocyte quickly leaves the peritoneal cavity and enters the infundibulum of the uterine tube.



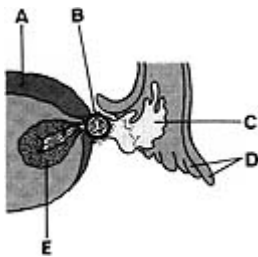
18.

Fimbriae

- a. A
- b. B
- c. C
- d. D
- e. E

ANS: D

The fimbriae of the uterine tube embrace the ovary at ovulation. The sweeping motion of the fimbriae and the motion of the cilia on their epithelial lining cells carry the oocyte into the uterine tube.



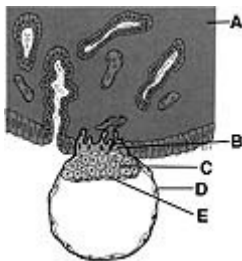
19.

Derived from a primary oocyte

- a. A
- b. B
- c. C
- d. D
- e. E

ANS: B

The secondary oocyte is derived from a primary oocyte after the first meiotic division. This division produces two haploid cells, the secondary oocyte and the first polar body. By the time of ovulation, the secondary oocyte has begun the second meiotic division but progresses only to the metaphase stage, where division is arrested. If the oocyte is fertilized, it completes the division, forming a mature oocyte.



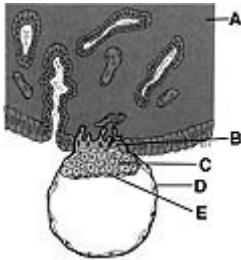
20.

_____ Cytotrophoblast

- a. A
- b. B
- c. C
- d. D
- e. E

ANS: D

The trophoblast of the implanting blastocyst differentiates into two layers. The internal layer is the cytotrophoblast. Rapid proliferation of cells of the cytotrophoblast give rise to the syncytiotrophoblast, a nucleated cytoplasmic mass.



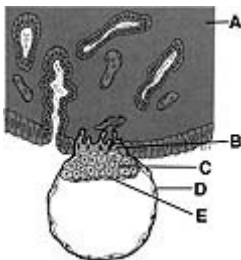
21.

_____ Embryoblast

- a. A
- b. B
- c. C
- d. D
- e. E

ANS: C

The embryoblast gives rise to the embryo. It arises from cells that have segregated from the morula. This occurs about 4 days after fertilization. The remaining cells of the morula become the trophoblast of the blastocyst.



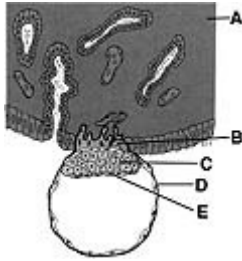
22.

_____ Endometrium

- a. A
- b. B
- c. C
- d. D
- e. E

ANS: A

The blastocyst attaches to the epithelium covering the compact layer of the endometrium about 6 days after fertilization. The endometrium is in the secretory phase of the uterine cycle, with abundant blood vessels and secreting glands. The endometrial cells are enlarged and filled with glycogen as well as lipids.



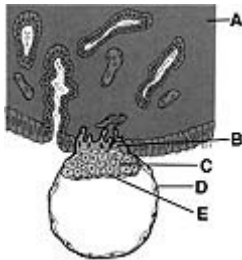
23.

_____ Hypoblast

- a. A
- b. B
- c. C
- d. D
- e. E

ANS: E

The hypoblast appears at about 7 days after fertilization. It is a flattened layer of cells on the surface of the inner cell mass facing the blastocyst cavity. The hypoblast gives rise to the embryonic endoderm and the endoderm of the umbilical vesicle.



24.

_____ Syncytiotrophoblast

- a. A
- b. B
- c. C
- d. D
- e. E

ANS: B

The syncytiotrophoblast, like the cytotrophoblast, is derived from the trophoblast. The trophoblast proliferates rapidly following implantation of the blastocyst. The syncytiotrophoblast is a multinucleated cytoplasmic mass with no discernible cell boundaries. The syncytiotrophoblast invades the uterine endometrium and facilitates implantation of the blastocyst.